

Journal of Biomedical Optics

BiomedicalOptics.SPIEDigitalLibrary.org

Optical coherence tomography provides an optical biopsy of burn wounds in children—a pilot study

Judith Lindert
Kianusch Tafazzoli-Lari
Ludger Tüshaus
Beke Larsen
Anna Bacia
Marie Bouteleux
Tina Adler
Valerie Dalicho
Vasileios Vasileiadis
Tobias Kisch
Felix Stang
Julia Welzel
Lutz Wunsch

SPIE.

Judith Lindert, Kianusch Tafazzoli-Lari, Ludger Tüshaus, Beke Larsen, Anna Bacia, Marie Bouteleux, Tina Adler, Valerie Dalicho, Vasileios Vasileiadis, Tobias Kisch, Felix Stang, Julia Welzel, Lutz Wunsch, "Optical coherence tomography provides an optical biopsy of burn wounds in children—a pilot study," *J. Biomed. Opt.* **23**(10), 106005 (2018), doi: 10.1117/1.JBO.23.10.106005.

Optical coherence tomography provides an optical biopsy of burn wounds in children—a pilot study

Judith Lindert,^a Kianusch Tafazzoli-Lari,^a Ludger Tüshaus,^a Beke Larsen,^a Anna Bacia,^a Marie Bouteleux,^a Tina Adler,^a Valerie Dalicho,^a Vasileios Vasileiadis,^{a,b} Tobias Kisch,^c Felix Stang,^c Julia Welzel,^d and Lutz Wunsch^{a,*}

^aUniversity Lübeck, Pediatric Surgery, Lübeck, Germany

^bUniversity Marburg, Pediatric Surgery, Marburg, Germany

^cUniversity Lübeck, Plastic Surgery, Lübeck, Germany

^dGeneral Hospital Augsburg, Dermatology, Augsburg, Germany

Abstract. Thermic injuries are among the most severe injuries in childhood. Burn depth is the most relevant prognostic factor, and still its assessment is both difficult and controversial. This diagnostic uncertainty results in repeated wound assessments over a 10-day period and carries a relevant risk for over- and undertreatment. Precise wound assessment would thus be a significant step toward improved care. Optical coherence tomography (OCT) is a noninvasive laser-based technique with a penetration depth of ~2 mm. It provides structural images of the skin while dynamic OCT (D-OCT) shows blood vessels. In this study, we investigated burns and scalds in 130 children with OCT and D-OCT to identify patterns of injury related to the depth of the burn wound. OCT and D-OCT images from burned skin differed consistently from normal skin. We observed several not formerly described morphologic patterns associated with burn injuries. Superficial wounds are characterized by a loss of the epidermal layer and a smooth surface. With deeper wounds, surface irregularity, loss of the dermal papillary pattern, disappearance of skin lines, and characteristic changes in the microvascular architecture were observed. This is the first systematic study of D-OCT in the assessment of burn wounds in children. A number of burn-associated patterns of injury were identified. Thus, D-OCT provided an “optical biopsy” of burn wounds that adds significant information about the severity of a burn wound. © 2018 Society of Photo-Optical Instrumentation Engineers (SPIE) [DOI: [10.1117/1.JBO.23.10.106005](https://doi.org/10.1117/1.JBO.23.10.106005)]

Keywords: burns in children; visualization skin; burn depth assessment; optical coherence tomography.

Paper 180197R received Apr. 2, 2018; accepted for publication Sep. 20, 2018; published online Oct. 15, 2018; corrected Feb. 1, 2019.

1 Introduction

Burns and scalds are among the most challenging injuries in childhood. Although the number of large burns is overall decreasing in developed countries, burns remain a major cause of trauma in children. Medium size burns and scalds frequently occur in early childhood and represent an important cause of long-term morbidity, disability, and disfigurement. Burns, even when treated with all modern modalities, often heal with significant scarring and functional impairment. Many aspects of diagnosis and treatment are controversial, and both over- and undertreatment are likely to contribute to poor results.

1.1 Burn Wound Assessment

The assessment of burn depth is the most controversial issue. Clinical judgement alone is most frequently used, but also expert judgement based on appearance, capillary refill, and sensibility has proved to be unreliable.^{1,2} Biopsies are the gold standard and have been used in many experimental studies, but their obvious disadvantages have limited their use in clinical practice.

In children, scald injuries are most frequent. They are characterized by a mixed pattern of injuries from superficial partial-thickness burns and deep partial thickness burns extending through the epidermis and dermis. The physiological response to thermic injuries involves overlapping stages of inflammation, tissue formation, and remodelling.

Clinically, superficial partial-thickness burns are characterized by capillary damage and cell swelling that result in blisters and edema. The basal cells of the epidermis remain intact and therefore allow spontaneous healing.

Deep partial-thickness burns cause significant vascular damage that leads to vascular occlusion, thrombosis, and edema, extending through the epidermis and dermis.^{3,4}

The status of the vascularity and degree of trauma to the microvascular plexus of the skin plays a key role.⁵

Burn wounds can be classified in retrospect by their healing tendency: by definition, a deep burn wound is not completely epithelialized at day 14 to 21 postinjury.⁶ However, this implies a long period of wound care and observation. The advantages of early grafting are lost and longer treatment results.

It would be clearly advantageous to know the depth and healing tendency of a burn wound at the earliest possible moment. Early wound closure, or, when unnecessary, reliable avoidance of skin grafting would improve the outcome and shorten the hospital stay. Reducing uncertainty and reassurance of the worried parents would be psychologically beneficial, too.

1.1.1 Optical coherence tomography and dynamic optical coherence tomography

Optical coherence tomography (OCT) is an imaging technique based on low-coherence interferometry to produce cross-sectional images from optical scattering of the laser beam

*Address all correspondence to: Lutz Wunsch, E-mail: lutz.wunsch@uksh.de

that provides structural information of the skin.^{7,8} It has been developed for the diagnosis of superficial skin lesions. In the skin, OCT visualizes the epidermis and the birefringence of dermal collagen fibers to a depth of 2 mm, with a very high resolution of 3 to 5 μm . Sectional images are obtained and subsequently reconstructed to produce an “en-face” view. Melanin does not affect OCT, which can be used regardless of the different skin types.^{7,8} However, the contrast between different tissues can be very low with the conventional OCT.

Dynamic-OCT (D-OCT) additionally exploits the speckle variance of repeated OCT scans, displaying changes of the signal caused by passing erythrocytes as blood flows.⁹ The blood flow and vascular anatomy are visualized. D-OCT is easily affected by movement and artifacts impair the image quality. The data for OCT and D-OCT are collected simultaneously.⁸⁻¹¹

The healing prognosis of large burn wounds is mainly determined by its depth, i.e., the degree of dermal loss and the damage to the microvasculature. Therefore, OCT and D-OCT potentially provide crucial information. To date, these techniques have not been applied to classify burns in children.^{8,10,11}

In this pilot study, burn wounds in children were systematically examined with OCT and D-OCT. The aim of our investigation is to provide a proof-of-principle that these techniques detect patterns of thermal injuries in children.

2 Patients and Methods

2.1 Clinical Setting

The children’s burn center at the Universitätsklinikum Schleswig-Holstein, Campus Lübeck is a dedicated children burn center in collaboration of the Departments of Pediatric Surgery, Plastic Surgery, and Pediatric Intensive Care. The children burn center is providing care to around 100 severely burned children every year. Institutional approval was obtained to start a study to investigate the role of OCT in children with burns. From May 2015 to January 2017, 130 consecutive patients were examined. Only patients whose families refused the scanning procedure were excluded. Most patients had multiple scans during scheduled dressing changes. Age ranged from 11 months to 15 years. Scans were taken from day 2 through day 12 after injury.

The study was funded by the University of Lübeck. No conflict of interest exists between the Vivosight Dx[®] company and any of the researchers.

2.1.1 Optical coherence tomography machine

The Vivosight Dx[®] OCT machine (Michelson Diagnostics Ltd., Kent, United Kingdom) was leased for the purpose of this study. The machine is licensed for clinical use and provides OCT and D-OCT images at the same time. It is a swept-source Fourier domain OCT based on multibeam technology and provides a resolution of <6 microns axially and <7.5 microns laterally. A scan includes a 6 mm \times 6 mm area of the skin with a scanning depth of \sim 2 mm. Acquisition of one scan requires 30 s and consists of 120 consecutive images. The OCT images were examined both on longitudinal sections and en-face views. En-face views are created from the three-dimensional reconstruction of the 120 longitudinal scans. En-face views were used for the interpretation of vascular patterns in D-OCT.

2.2 Study Protocol

A scanning protocol including special adaptations to ensure sterile working and scanning conditions was developed. For each scan, digital pictures of the scan area and the surrounding wound were taken and the position of the scanning device recorded. All scans were taken during routine procedures under general anaesthesia or sedation. An additional physician performed the scans to avoid any procedural delays. In addition to the burn wound, an area of healthy skin near the wound or in a corresponding contralateral localization was scanned for comparison.

The wound scans were reviewed and compared to normal skin and clinical outcomes.

3 Results

Because knowledge of normal OCT and D-OCT in the skin of children is limited, normal findings are summarized first. Findings related to burn wounds can be classified as epidermal, dermal, and vascular.

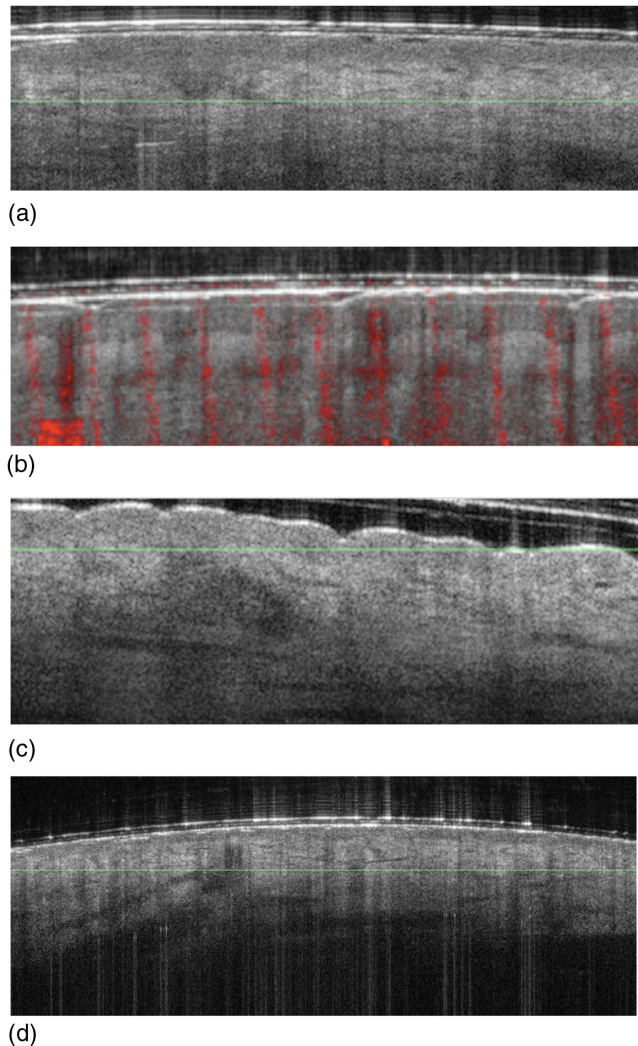


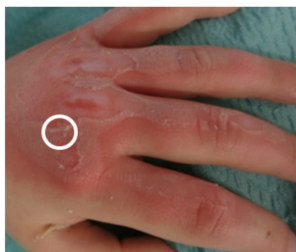Fig. 1 Standard OCT of healthy skin: (a) longitudinal view of the epidermis and dermoepidermal junction in hair bearing skin, (b) longitudinal view of nonhair bearing skin, (c) longitudinal view of shoulder region with typical surface irregularity, and (d) longitudinal view of face skin. Root of the hair visualized.

3.1 Normal Skin Anatomy

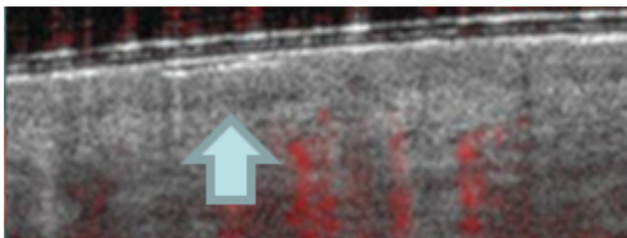
OCT images of normal skin (see Fig. 1) show regional differences but the epidermis and the dermoepidermal junction can be usually distinguished [see Fig. 1(a)]. The epidermis is a dark band with granular texture. In nonhair bearing skin, the epidermis is much thicker and sweat glands are visible [see Fig. 1(b)]. A fine surface irregularity is observed in the shoulder region [see Fig. 1(c)].

At the dermoepidermal junction, the typical structure of the papillary dermis is best appreciated with en-face views, where a regular pattern of circular openings exists. The typical skin lines of nonhair-bearing skin can be typically traced to this level [see Fig. 6(a)].

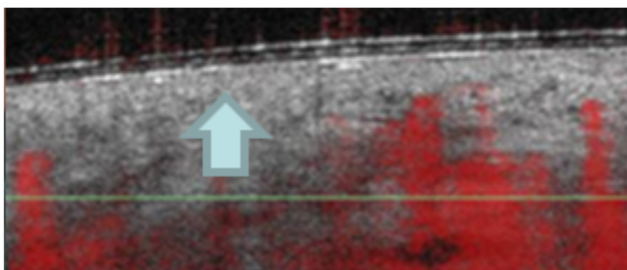
D-OCT shows the two vascular plexus: the superficial plexus with the arterial capillaries forming the dermal papillary loops and the deep plexus [see Fig. 7(a)]. Due to the different epidermal thickness in various body regions, the vascular plexus is found at different depths. In the longitudinal view, the microvascular network is characterized by small dots displayed in red colour. The en-face view shows an organized microvascular network with a regular branching pattern. Individual vessels can be identified.



(a)

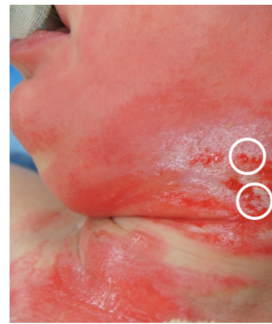


(b)

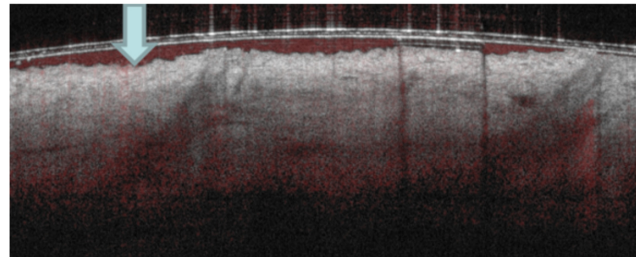


(c)

Fig. 2 Loss of epidermis: (a) OCT Image of the contralateral healthy dorsal side of the hand. The arrow shows the intact epidermis as a dark band. (b) Image of a scald injury on the dorsal side of the hand. Encircled areas scanned with OCT. (c) OCT image of a scald injury on the dorsal side of the hand. No dark band representing the epidermis.



(a)



(b)

Fig. 3 Surface irregularity. (a) Photograph of surface irregularity in scald injury on the face. Encircled areas scanned with OCT and (b) longitudinal view of surface irregularity in scald injury. Arrow points on irregularity.

3.2 Epidermal Loss and Irregular Surface

3.2.1 Epidermal loss

Epidermal loss typically occurs with blister formation. The epidermis is lifted from the wound [as seen on the photograph Fig. 2(a) of a scald injury of the dorsum manum], and on the OCT images after blister removal and wound debridement, the typical dark line [see Fig. 2(b)] is lost. Figure 2(c) shows a typical example of a second degree burn with loss of epidermis in the OCT image [see Fig. 2(c)] and a relatively smooth surface. This wound healed completely within 10 days.

3.2.2 Skin surface irregularity

Most thermal injuries may produce wounds with irregular borders and variable depth as seen in the photograph of a scald injury on the face and neck area [Fig. 3(a)]. The smooth surface of the skin is disrupted and an irregular surface pattern emerges [Fig. 3(b)]. Surface irregularity increases with the evolution of the wound and after debridement. These features are most obvious with OCT longitudinal sections.

3.3 Disruption of Dermal Patterns

3.3.1 Loss of papillary pattern

The en-face view also displays a characteristic pattern of small, dark openings at the level of the papillary dermis [see Fig. 4(a)]. They represent the openings in the dermal matrix for the hair follicles and the vessels of the papillary vascular plexus. The openings are regularly spaced and mark the papillary layer of the dermis, the loss of this pattern [see Figs. 4(a) and 4(b)] points to a lesion that reaches the reticular layer of the dermis. This pattern was typically observed in hair-bearing skin.




Fig. 4 Papillary pattern. (a) En face view of normal papillary pattern, (b) en face view of destroyed papillary pattern, and (c) scald injury of the elbow region.

Figure 4(c) shows a picture of a scald injury on the upper arm with loss of the dermal pattern. This injury required a skin graft later.

3.3.2 Loss vascular and lymphatic spaces

Normal skin shows linear spaces in the dermis that correspond to blood and lymphatic vessels in the optical coherence tomography image, as visualized in Fig. 5(a). In some of the deeper injuries, these spaces disappeared. Figure 5(b) visualizes an example of a deep burn of the shoulder with absent vascular spaces as no dark

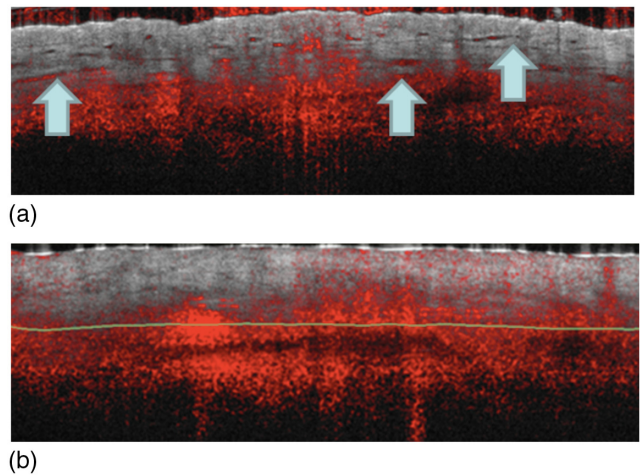


Fig. 5 Loss of vascular and lymphatic spaces. (a) Healthy skin of the shoulder region with regular vascular spaces in the dermis pointed out by the arrows and (b) scald injury with absent vascular spaces in the dermis.

lines are present in the longitudinal view. This injury required grafting. For comparison, the healthy skin of the other shoulder is shown. The characteristic wrinkling of the healthy skin of the shoulder area in Fig. 5(a) should also be noted.

3.3.3 Loss of skin lines

Skin lines are a characteristic feature of the glabrous skin of the palms of the hand and the soles of the feet. Skin lines can be easily recognized with the OCT en-face view. In burn wounds of the hand, skin lines that were invisible clinically could be

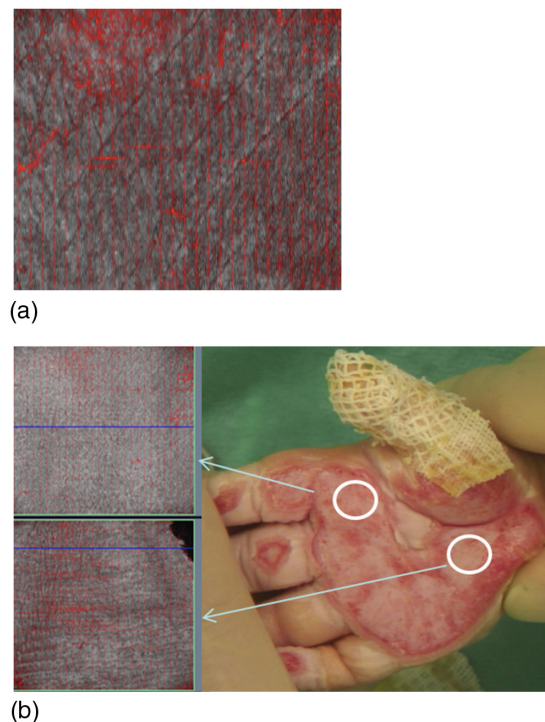


Fig. 6 Skin lines. (a) En-face view of skin lines in healthy skin. (b) Upper circle and upper OCT image: skin lines effaced this area later required grafting. Lower circle and lower OCT image skin lines still present in the en-face OCT image.

traced by OCT. Preserved skin lines [see Fig. 6(b)] were associated with spontaneous healing, whereas skin grafts were required when the line pattern was completely erased. Figure 6 represents two regions of a hand following a contact burn. The two marked regions appeared clinically similar, but only the region with the undetectable skin lines [Fig. 6(a)] required skin grafting.

3.3.4 Thrombosis of the vascular plexus

En-face views of D-OCT display blood flow and the normal pattern of the dermal plexus, as shown in Fig. 7(a). The vascular ramifications in normal skin show a gradual reduction of vessel




Fig. 7 Microvasculature visualized with D-OCT en face views. (a) En face view of normal microvascular network. (b) En face view: absence of fine normal microvascular network only large disrupted vessels visualized. (c) Obliteration of vessels with suspicion of thrombosis.

size. In deep burn wounds, the normal architecture of the vascular plexus was undetectable. In other wounds, the vascular pattern was altered, see Fig. 7(b). The fine vascular network disappeared and only some relatively large dermal vessels were detected. They do not show the characteristic ramifications but ended abruptly, suggesting a microvascular thrombosis, see Fig. 7(c).

For comparison, in the lower part of the wound and on the right (arrows), this pattern is lost.

4 Discussion

Our research provides a proof-of-principle that OCT and D-OCT detect patterns of thermal injuries in children. Some of these patterns have not been previously reported.

4.1 Patterns of Thermal Injury in Children

OCT reliably detects epidermal injuries as irregularities or loss of the characteristic surface structure. Epidermal loss corresponds clinically to superficial lesions, in which spontaneous healing can be expected when no additional damage to dermal structures has occurred. Epidermal injuries are readily detected clinically.

Dermal injuries are characterized by the loss of skin lines in glabrous skin, loss of the papillary pattern, and loss of dermal spaces. These changes reflect injury to the collagen matrix architecture. These findings were found with and without vascular pattern changes. These dermal changes are not easily distinguished clinically and may be responsible for the disagreement among different clinicians. Contact burns of the hands are frequent in children and exploring the prognostic significance of the loss of skin lines is promising.

Damage to the vascular plexus reflects severe injuries with potentially poor healing prognosis. Clinically, wound perfusion is assessed by the observation of blanching after compression and scarification. The imaging of the dermal plexus with D-OCT holds the potential for a more nuanced assessment. However, cardio circulatory status and temperature may influence dermal perfusion and must be considered.

Histologic studies have shown that damage to the microcirculation is the most relevant sign of deep burns.^{9,12} The visualization of obliterated vascular spaces may correspond to the tissue coagulation found in deep burn wounds. D-OCT is of particular interest, because the density and the branching pattern of the microvessels can be observed. Gong et al.¹² showed markedly increased density of the vasculature and increased vessel diameters compared to contralateral healthy skin. In our study, absent microvessels were associated with deep burns requiring skin grafts.

Some differences between the microvascular pattern in burn wounds and normal plexus anatomy were found. In healthy skin, regular branching of vessels with a gradual decrease in size is observed. In burns, superficial vessels disappeared, and larger “truncated” vessels without branching were seen. Characteristic changes of the microvascular architecture in burns requiring grafting later have been defined in our observations as well as changes in the microvessel architecture already known from other dermatological conditions and studies on burned adult skin.^{8,10,12}

Several limitations of our protocol and the technique inevitably emerged during this pilot study. Our probe scanned only a small area, so a sampling error may occur if the region of interest is not scanned. Technical improvements to allow the

assessment of larger wounds are highly desirable. From the moment of injury, the burn wound is in dynamic evolution and timing may have influenced some of our results. The scanning procedure needs improvement; it was difficult to avoid undesired motion or variations of pressure of the transducer leading to artifacts and impaired image quality and information value.

4.2 Other Imaging Technologies

Among several imaging techniques that have been developed, laser Doppler imaging (LDI) is the most relevant.

LDI is based on the Doppler principle: light that hits moving blood cells undergoes a change in wavelength/frequency (Doppler shift), whereas light that encounters static structures returns unchanged. The perfusion and the microcirculatory blood flow are then calculated. LDI provides an objective real-time evaluation and is used in burn wound depth assessment. LDI can scan areas up to 50×50 cm, generating a color-coded perfusion image, which reflects the perfusion. The method has shown its ability to detect different burn depth in children.^{2,13} However, it requires informed interpretation for a reliable diagnosis of burn depth.⁵ No information about morphological changes in the wound is obtained. LDI is also influenced by several confounding factors: body shape, illumination, blood pressure, temperature, skin color and moisture, blisters, and wound infection.² Laser speckle imaging produces similar results.

Other noninvasive optical techniques for wound imaging include hyperspectral imaging, multispectral imaging, near-infrared spectroscopy (NIRS), and diffuse reflectance spectroscopy. These techniques visualize the oxygenation of the wound and reflect cutaneous oxygenation.

Spatial frequency domain imaging is an extension of NIRS with the same imaging physics but a different processing of the records. All technologies are currently at various stages of clinical evaluation to define their clinical usefulness.⁷

Fluorescence imaging visualizes fluorescent molecules in tissues via autofluorescence and in studies detects clinically relevant bacterial load during debridement.⁷

Among the techniques reported, OCT and D-OCT are the techniques only to provide simultaneously detailed structural and functional information of the burn wound. Our pilot study proved the feasibility of OCT and D-OCT in the setting of burn care in children. We defined distinctive patterns of thermal injuries in children that were reliably absent in normal skin. These findings provide a promising starting point for future investigations of sensitivity and specificity, differences of body regions, age and wound healing in general. D-OCT focusing on the characteristics of the dermis in postburn scars

in already established scars showed a lower dermal attenuation in the scar areas compared to healthy skin.

With the actually dismal outcome of many burn injuries, the information provided by OCT and D-OCT is highly welcome to contribute to improve diagnosis and care. Further technical improvements to allow the speedy examination of large surface areas would also improve usability and reduce sampling error.⁵

Disclosures

There are no conflicts of interests to disclose.

Acknowledgments

We would like to thank all patients taking part in the study. Furthermore, we thank all colleagues and theater staff engaged in the research to pilot optical imaging technologies to improve burn wound assessment in children. Source of funding: University Lübeck.

References

1. S. Monstrey et al., "Assessment of burn depth and burn wound healing potential," *Burns* **34**, 761–769 (2008).
2. A. M. Watts et al., "Burn depth and its histological measurement," *Burns* **27**(2), 154–160 (2001).
3. J. E. Thatcher, J. J. Squiers, and S. C. Kanick, "Imaging techniques for clinical burn assessment with a focus on multispectral imaging," *Adv. Wound Care* **5**(8), 360–378 (2016).
4. J. W. Shupp et al., "A review of the local pathophysiologic bases of burn wound progression," *J. Burn Care Res.* **31**, 849–873 (2010).
5. A. J. Singer and R. A. F. Clark, "Cutaneous wound healing," *N. Engl. J. Med.* **341**, 738–746 (1999).
6. B. S. Atiyeh, S. W. Gunn, and S. N. Hayek, "State of the art in burn treatment," *World J. Surg.* **29**, 131–148 (2005).
7. M. Jayachandran et al., "Critical review of noninvasive optical technologies for wound imaging," *Adv. Wound Care* **5**(8), 349–359 (2016).
8. P. Ganapathy et al., "Dual-imaging system for burn depth diagnosis," *Burns* **40**, 67–81 (2014).
9. M. Ulrich et al., "Dynamic optical coherence tomography in dermatology," *Dermatology* **232**(3), 298–311 (2016).
10. P. Gong et al., "Assessment of human burn scars with optical coherence tomography by imaging the attenuation coefficient of tissue after vascular masking," *J. Biomed. Opt.* **19**, 021111 (2014).
11. N. Iftimia et al., "Combined reflectance confocal microscopy/optical coherence tomography imaging for skin burn assessment," *Biomed. Opt. Express* **4**, 680–695 (2013).
12. P. Gong et al., "Optical coherence tomography angiography for longitudinal monitoring of vascular changes in human cutaneous burns," *Exp. Dermatol.* **25**, 722–724 (2016).
13. A. J. Holland, H. C. Martin, and D. T. Cass, "Laser Doppler imaging prediction of burn wound outcome in children," *Burns* **28**, 11–17 (2002).

Biographies for the authors are not available.